

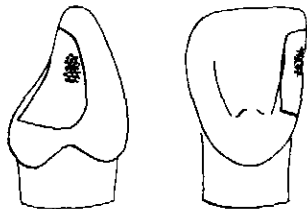
THE INCONSPICUOUS CLASS III POWDERED GOLD RESTORATION
(HAND CONDENSED)

CREIGHTON UNIVERSITY SCHOOL OF DENTISTRY

GENERAL CONSIDERATIONS

1. ALL INSTRUMENTATION OF CUTTING AND CONDENSING IS ACCOMPLISHED FROM THE LINGUAL ASPECT. THE PURPOSE IS TO PROVIDE A 5-WALLED CAVITY PREPARATION INTO WHICH GOLD IS CONDENSED. SIDE WALLS OF THE PREPARATION ARE FORMED BY THE AXIAL WALL AND ADJACENT TOOTH. THE INCISAL WALL AND GINGIVAL SEAT FORM THE OTHER SIDE WALLS. THE LABIAL WALL FORMS THE FLOOR. FOR EASIER CONDENSATION AND FOR BETTER ESTHETICS, THE LABIAL MARGIN SHOULD NOT BE EXTENDED ANY FURTHER LABIALLY THAN NECESSARY.

*outline
form*



2. THE GINGIVAL SEAT IS EXTENDED FURTHER GINGIVALLY AT THE LABIAL THAN AT THE LINGUAL, REDUCING THE AMOUNT OF TOOTH STRUCTURE LOST IN THE LINGUAL AREA AND THUS ALLOWING FOR FUTURE RETENTION.
3. THE MARGINAL RIDGE IS OPENED WIDELY FOR ACCESS AND TO ESTABLISH A FLAT AXIAL WALL IN DENTIN.
4. WHEN POSSIBLE, THE INCISAL MARGIN IS EXTENDED INTO THE INCISAL EMBRA-SURE BEYOND THE CONTACT POINT.
5. NO SHORT BEVELS ARE PLACED ON THE CAVO-SURFACE. INSTEAD, A NEARLY 90° ANGLE IS ACHIEVED WHERE THE WALLS JOIN THE CAVO-SURFACE.
6. RETENTION IS PROVIDED BY 3 DISTINCT AREAS WHICH ARE BULKY AND ROUNDED TO FACILITATE PLACEMENT OF POWDERED GOLD. LINE ANGLES ARE PLACED BETWEEN THESE RETENTION AREAS.

MINIMUM ARMAMENTARIUM

PREPARATION:

2 GINGIVAL MARGIN TRIMMERS (10-80-7-14; 10-95-7-14) OR
LINGUAL ANGLE FORMERS (9-7-23-16-R; 9-7-23-16-L)
#700 TAPERED FISSURE BUR (CA) # $\frac{1}{2}$ ROUND BUR (CA)

CONDENSATION:

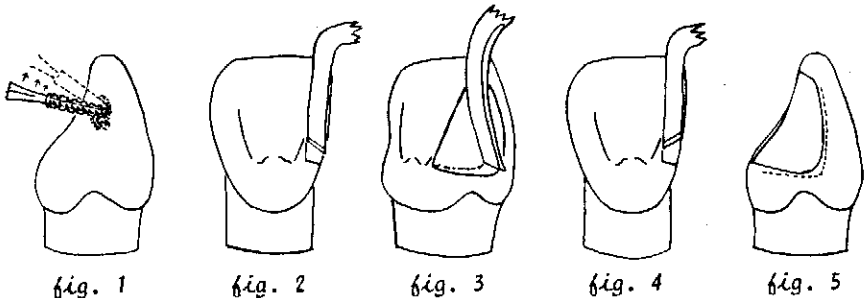
3 GOLD FOIL HAND CONDENSERS (21-R; 21-L; 23-24)
POWDERED GOLD PELLETS
GOLD FOIL CARRIER ALCOHOL FLAME

FINISHING:

MECHANICAL SEPARATOR
GOLD FOIL KNIFE (PULL BLADE)
DISCOID
HAND BURNISHER
ASSORTED FINISHING STRIPS
FINISHING STONES
RUBBER CUPS
FLOUR OF PUMICE
TIN OXIDE

PREPARATION

1. INITIAL OPENING IS ACCOMPLISHED WITH A #700 TAPERED FISSURE BUR INTRODUCED FROM THE LINGUAL; THE BULK OF THE MARGINAL RIDGE IS REMOVED. THE END OF THE BUR IS USED TO ESTABLISH THE LABIAL WALL; THE SIDE OF THE BUR ESTABLISHES THE AXIAL WALL.
2. TO ACCOMPLISH INCISAL EXTENSION, THE BUR IS INCLINED INCISALLY (*fig. 1*). INCISAL EXTENSION MAY BE COMPLETED WITH A LARGER ROUND BUR OR HAND INSTRUMENT IF DEEMED NECESSARY.



3. REMAINING EXTENSION AND PLANING OF WALLS CAN BE ACCOMPLISHED WITH A GINGIVAL MARGIN TRIMMER OR LINGUAL ANGLE FORMER. THE LINGUAL MARGIN AND AXIAL WALL CAN BE SMOOTHED WITH THE SIDE OF THE BLADE (*fig's. 2 & 3*).
4. THE LINE ANGLE FORMED BY THE JUNCTION OF THE AXIAL AND LABIAL WALLS PLUS THE ANGLE FORMED BY THE AXIAL AND GINGIVAL WALLS ARE SHARPENED WITH THE OPPOSITE GINGIVAL MARGIN TRIMMER OR LINGUAL ANGLE FORMER (*fig's. 4 & 5*).
5. THE 3 RETENTION AREAS MAY BE PLACED IN MUCH THE SAME WAY AND IN THE SAME AREAS AS IS COMMONLY DONE FOR CLASS III SILICATE PREPARATIONS. PLACE AND ENLARGE THE RETENTION WITH A # $\frac{1}{2}$ ROUND BUR (*fig's. 6 & 7*). NOW REMOVE REMAINING CARRIES FROM AXIAL WALL.

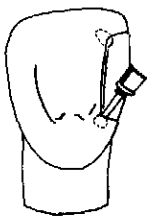


fig. 6

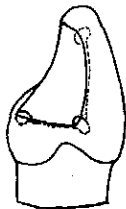


fig. 7

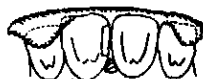

fig. 8

MATRIX ADAPTATION (fig. 8)

1. THIS STEP IS APPLICABLE ONLY WHEN THE LABIAL WALL IS NECESSARILY OVER-EXTENDED. OTHERWISE CONDENSATION MAY BE COMMENCED. THIS PROCEDURE HELPS TO PROVIDE FOR THE MISSING FLOOR (LABIAL WALL) OF THE 5-WALLED PREPARATION INTO WHICH GOLD IS CONDENSED.
2. INSERT A WOODEN WEDGE FROM THE LABIAL JUST BELOW THE GINGIVAL MARGIN.
3. SOFTEN AND INSERT GUTTA PERCHA INTO THE PREPARATION ALLOWING A SMALL PORTION TO EXUDE OVER THE LABIAL MARGIN.
4. APPLY A SMALL AMOUNT OF QUICK-CURE ACRYLIC OVER THE LABIAL PORTION OF THE ANTERIOR TEETH. LOCK THE ACRYLIC IN PLACE WITH 2 TAGS OVER THE INCISAL EDGES OF THE MOST DISTAL TEETH.
5. REMOVE GUTTA PERCHA FROM THE LINGUAL JUST AS THE HEAT OF POLYMERIZATION BEGINS. WATER COOL THE ACRYLIC AS THE EXOTHERMIC REACTION CONTINUES.

CONDENSATION

1. AFTER ANNEALING, PLACE A SMALL POWDERED GOLD PELLET INTO THE LABIO-GINGIVAL RETENTION. SINCE THIS TYPE OF GOLD HOLDS HEAT FOR A TIME, WAIT A FEW SECONDS BEFORE INTRODUCING IT INTO THE PREPARATION. CONDENSE THIS PELLET WELL INTO PLACE, USING THE ROUND NIB OF CONDENSER #21-R or #21-L (fig. 9). THIS PELLET AND ALL FUTURE PELLETS USED SHOULD BE CAREFULLY SPREAD OUT AFTER FIRST BEING TACKED INTO PLACE. THE GOLD SHOULD BE WELL STEPPED TO AVOID BRIDGING (VOIDS). BETTER RESULTS ARE OBTAINED BY USING SMALL PELLETS, BY USING A ROCKING MOTION DURING CONDENSATION, BY USING THE PALM AND THUMB GRASP TO EXERT PRESSURE, AND BY USING THE SMALLER-FACED CONDENSERS WHEREVER POSSIBLE.
2. THE NEXT PELLET SHOULD BE CONDENSED ALONG THE AXIO-GINGIVAL LINE ANGLE TOWARD THE LINGUO-GINGIVAL RETENTION. MANY TIMES THIS PELLET WILL EXTEND INTO THE RETENTION. IF SO, THE BAYONET CONDENSER (#24) IS USED TO PROVIDE A LINGUAL DIRECTION OF FORCE IN FILLING THIS RETENTION (fig. 10). IF NOT, PLACE ANOTHER PELLET INTO THIS RETENTION BEFORE CONDENSING LINGUALLY.

3. AFTER COMPLETION OF THIS TRIANGULAR BAR, TEST ADAPTATION WITH AN EXPLORER.
4. COVER THE LABIAL AND GINGIVAL WALLS WITH GOLD USING THE ANGLED NIB OF THE #21-R (FOR RIGHT EXPOSURES) OR THE #21-L (FOR LEFT EXPOSURES). THE SHAPE OF THE INSTRUMENT'S FACE ALLOWS YOU TO BANK THE GOLD OVER THE MARGINS AS YOU STEP (fig's 11 & 12). ALTERNATE WITH THE OTHER END OF THE INSTRUMENT IN CONDENSING THE BULK OF THE GOLD EXTENDING TOWARD THE LINGUAL OF THE PREPARATION.

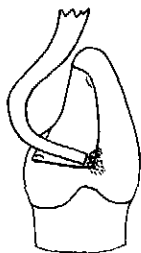


fig. 9

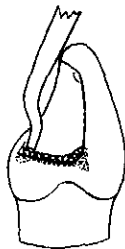

fig. 10

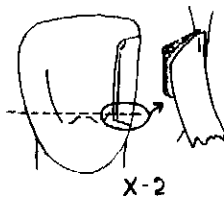


fig. 11

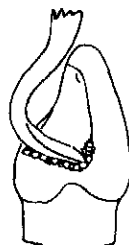

fig. 12

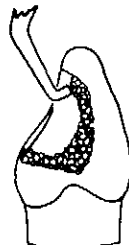

fig. 13

5. AS THE INCISAL IS APPROACHED DURING CONDENSATION, EASE INTO THE INCISAL RETENTION. USE THE #23 CONDENSER WITH A PULLING MOTION FROM AN INCISAL DIRECTION WHEN FILLING THIS RETENTION (fig. 13).
6. COMPLETE THE PROXIMAL CONDENSATION WITH THE #21 ANGLED CONDENSER. BUILD GOLD AGAINST THE ADJACENT TOOTH TO PREVENT PITTING THE GOLD IN THE CONTACT AREA OF THE RESTORATION. THE REMAINING BULK OF THE LINGUAL SURFACE AND MARGINAL RIDGE MAY BE CONDENSED WITH THE ROUND NIB OF THE #21 CONDENSER.

FINISHING

1. IF UTILIZED, REMOVE MATRIX AND WOODEN WEDGE.
2. APPLY MECHANICAL SEPARATOR. IN CASES WHERE THE MATRIX HAS BEEN USED, ADDITIONAL CONDENSATION OF THE LABIAL, IF NECESSARY, MAY NOW BE ACCOMPLISHED.
3. BURNISH OVER THE LABIAL MARGIN WITH A SMALL DISCOID. PULL THE GOLD TOWARD AND OVER THE LABIAL MARGIN.
4. REMOVE EXCESS GOLD INTERPROXIMALLY FROM GINGIVAL MARGIN TO THE CONTACT AREA WITH A GOLD KNIFE. BE CAUTIOUS AS CUTTING INSTRUMENTS TEND TO TEAR POWDERED GOLD.
5. REMOVE BULK OF EXCESSIVE LINGUAL GOLD WITH FINISHING STONES.
6. BURNISH LINGUAL SURFACE WITH A SMOOTH-SURFACED HAND BURNISHER.
7. USE FINISHING STRIPS WITH DECREASING GRIT TO OBTAIN FINAL CONTOUR.
8. USE PUMICE AND TIN OXIDE FOR FINAL POLISHING AND FINAL LUSTRE.